

Memory Repression: Brain Mechanisms underlying Dissociative Amnesia

Hirokazu Kikuchi, Toshikatsu Fujii, Nobuhito Abe, Maki Suzuki, Masahito Takagi, Shunji Mugikura, Shoki Takahashi, and Etsuro Mori

Abstract

■ Dissociative amnesia usually follows a stressful event and cannot be attributable to explicit brain damage. It is thought to reflect a reversible deficit in memory retrieval probably due to memory repression. However, the neural mechanisms underlying this condition are not clear. We used fMRI to investigate neural activity associated with memory retrieval in two patients with dissociative amnesia. For each patient, three categories of face photographs and three categories of people's names corresponding to the photographs were prepared: those of "recognizable" high school friends who were acquainted with and recognizable to the patients, those of "unrecognizable" colleagues who were actually acquainted with but unrecognizable to the patients due to their memory impairments, and "control" distracters who were unacquainted with the patients. During fMRI, the

patients were visually presented with these stimuli and asked to indicate whether they were personally acquainted with them. In the comparison of the unrecognizable condition with the recognizable condition, we found increased activity in the pFC and decreased activity in the hippocampus in both patients. After treatment for retrograde amnesia, the altered pattern of brain activation disappeared in one patient whose retrograde memories were recovered, whereas it remained unchanged in the other patient whose retrograde memories were not recovered. Our findings provide direct evidence that memory repression in dissociative amnesia is associated with an altered pattern of neural activity, and they suggest the possibility that the pFC has an important role in inhibiting the activity of the hippocampus in memory repression. ■

INTRODUCTION

Repression is a process proposed by Freud in which unpleasant memories can be purged from consciousness (Freud, 1966). Although some researchers claim that memory repression is a clinical myth (Kihlstrom, 2002), others have provided evidence that memory suppression is an active forgetting process and a laboratory analog of unconscious memory repression (Depue, Banich, & Curran, 2006; Anderson & Green, 2001). Furthermore, recent fMRI studies have shed light on the neural mechanisms involved in voluntary memory suppression. Anderson et al. (2004) reported that increased activity of the bilateral dorsolateral pFC (DLPFC) and decreased activity of the hippocampus were involved in motivated exclusion of unwanted memories from awareness. Depue, Curran, and Banich (2007) also argued that emotional memory is suppressed by two pathways from the right inferior frontal gyrus and the right middle frontal gyrus, and that the latter pathway controls memory representations in the hippocampus and the amygdala. More recently, Mendelsohn, Chalamish, Solomonovich, and Dudai (2008) reported that posthypnotic amnesia caused by a suggestion to forget memory is associated with increased activity in the left rostrolateral pFC and reduced activity in multiple brain regions, including the left temporal and occipital

cortices. These studies have consistently shown the contribution of the pFC to voluntary memory suppression.

It should be noted, however, that Freud's theory related to repression changed over time (Erdelyi, 2006). Freud's original concept of repression was an intentional attempt to prevent unwanted experiences from entering conscious awareness. He later used the term to refer to one of several defense mechanisms operating automatically outside a person's awareness. The studies cited above supported Freud's early idea about repression in that they confirmed that intention can suppress memory, and they delineated its neural correlates in nonpsychiatric populations (Schacter, 2001). However, the neural mechanisms that might underlie Freud's later idea concerning an involuntary mechanism of repression have not yet been elucidated, and corresponding clinical evidence is still lacking (Anderson & Levy, 2002).

Dissociative amnesia, a psychiatric disorder in which patients have an inability to retrieve specific (unpleasant) memories, might provide an important clue with regard to this issue. It usually follows a traumatic or stressful autobiographical event and is not due to any direct physiological effects of a neurological or other general medical condition (American Psychiatric Association, 1994) and is, therefore, presumed to be psychogenic in origin. Dissociative amnesia often occurs very soon after traumatic events (i.e., insoluble and intolerable problems) but sometimes arises in association with continuous internal conflict or an ongoing

intolerable situation (Kaplan & Sadock, 1995). This disorder is usually considered to be a way of managing the conflict or painful affects of the problems. Although some researchers have argued that dissociative amnesia can be caused by an altered release or imbalance of stress hormones and transmitter agonists at the brain level (Markowitsch, 1999, 2003; de Kloet, Oitzl, & Joels, 1999), little is known about its underlying mechanisms.

There have been some neuroimaging studies of dissociative amnesia, but the findings are diverse and the interpretation of the data is still controversial. Some PET studies with a single patient have reported reduced activity in the right hemisphere (Markowitsch, Fink, Thone, Kessler, & Heiss, 1997), reduced activity in the right frontal and temporal regions (Markowitsch, Calabrese, et al., 1997), and reduced activity of the hippocampus with increased activity of the anterior medial-temporal lobe (MTL) including the amygdala (Yasuno et al., 2000) during memory retrieval tasks. In fMRI experiments, Yang et al. (2005) investigated a patient with dissociative amnesia and showed deactivation in the MTL when the patient was viewing faces that were unrecognizable to her because of her memory impairment. Botzung, Denkova, and Manning (2007) reported a patient who showed greater activity in the posterior cortical regions and reduced activity in the frontal networks and left MTL, associated with the retrieval of autobiographical memory stemming from the forgotten period. Hennig-Fast et al. (2008) showed that during the patient's acute state, the temporo-occipital part of the network known to be related to autobiographical memory was not activated. Although the findings of the fMRI experiments tend to indicate dysfunction of the MTL in patients with dissociative amnesia, the reason why the deactivation occurs in the regions responsible for memory processing has not been fully clarified. According to one notable theoretical model, frontal control systems precipitate memory inhibition in dissociative amnesia (Kopelman, 2000, 2002). This theory, together with fMRI studies with healthy participants (Mendelsohn et al., 2008; Depue et al., 2007; Anderson et al., 2004), led us to hypothesize that prefrontal regions play an important role in dissociative amnesia.

In the present study, we conducted fMRI experiments combined with face and name recognition tasks in two patients with dissociative amnesia: Patient 1, a 27-year-old man, and Patient 2, a 52-year-old man. Both patients had profound and time-limited retrograde amnesia; for Patient 1, it involved the period between his last half year at college and onset (approximately 4.5 years), and for Patient 2, it involved the period from his time at university to onset (approximately 35 years). Both patients could easily retrieve autobiographical memories for the years between childhood and high school. After therapeutic sessions of interview using intravenous injection of sodium thiopental (Kopelman, 2000, 2002), Patient 1 could recover most of the memories he had lost due to amnesia, whereas the retrograde amnesia of Patient 2

remained unchanged. These rare cases enabled us to investigate systematically the neural mechanisms underlying dissociative amnesia with a well-controlled experimental design. To our knowledge, the present study is the first to provide direct evidence that dissociative amnesia is associated with prefrontal activation and hippocampal deactivation.

METHODS

Participants

Two patients who were diagnosed as having dissociative amnesia participated in this study (for details, see Case report on Patient 1 and Case report on Patient 2). Both patients gave written informed consent in accordance with the Declaration of Helsinki.

Case Report on Patient 1

Patient 1 was a 27-year-old, right-handed, unmarried man. He had normal developmental and educational histories and had worked as a businessman for about 4 years after graduating from college. He was described by his mother as a scrupulous person.

One weekday morning, he suddenly suffered from retrograde amnesia and said later, "When I woke up, I wondered what room I was in and where I was. I found my ID card in my wallet, which showed that I was a company businessman, but I was not otherwise aware of that fact." After 2 days of fugue, he was admitted to a hospital, and a month later was transferred to our hospital.

Patient 1 was alert and cooperative. On the first day of our assessments, he thought he had retrograde amnesia covering a period of 4 years preceding onset but that was later corrected to 4 1/2 years after assessment. He could remember events that had occurred after the onset. He also understood that he could remember past events and facts that had been taught to him by the people around him after the onset, and he could distinguish what he had relearned from what he originally remembered of the past events that he could retrieve. He was upset about his retrograde amnesia, but his attitude was mature and intelligent. His mother reported that his personality remained basically unchanged. He had no physical or neurological symptoms. His blood and cerebrospinal fluid, MRI, and SPECT of his brain were normal, as was his EEG.

Table 1 shows the results of the neuropsychological assessments of Patient 1. He was intelligent, and his attention, language, and frontal lobe function were normal. Examinations such as the Wechsler Memory Scale—Revised (WMS-R) showed that his anterograde memory was intact. To assess his retrograde memory, he underwent the Autobiographical Memory Interview, the Crovitz Test, a personally adjusted Public Event and People Test, and a structured interview. These examinations revealed that he had retrograde amnesia for the 4.5 years preceding onset, that is, the last half year of his time at college and all 4 years of the

Table 1. Standard Neuropsychological Examinations of Patient 1 and Patient 2

<i>Examination</i>		<i>Patient 1</i>	<i>Patient 2</i>		
Intelligence	MMSE (out of 30)	30	30		
	WAIS	Verbal IQ	120	121	
	WAIS-R on Patient 1	Performance IQ	119	108	
	WAIS-III on Patient 2	Full-scale IQ	120	117	
Attention	Digit span	Forward	8	7	
		Backward	7	6	
	Spatial span	Forward	6	8	
		Backward	7	6	
Language	WAB	Aphasia quotient	100	100	
Frontal lobe function	WCST	Categories achieved	6	6	
		Perseverative errors of Nelson	0	1	
		Difficulty in maintaining set	0	0	
	Verbal fluency	“Fu” + “A” + “Ni”	34	31	
		Animals	18	19	
	TMT	Part A	38.4 sec	38.7 sec	
		Part B	67.3 sec	67.7 sec	
		FAB (out of 18)	18	18	
	Anterograde memory	WMS-R	Verbal memory quotient	99	114
			Visual memory quotient	116	119
General memory quotient			105	117	
Attention/concentration			120	131	
Delayed recall			109	123	
Rey figure		Copy (out of 36)	36	36	
		Immediate recall (out of 36)	34	28	
		30 min. delayed recall (out of 36)	34	27	
	AVLT (out of 15)	7-11-12-12-14	5-6-7-11-11		

MMSE = Mini-Mental State Examination; WAIS-R or WAIS-III = Wechsler Adult Intelligence Scale—Revised or Third Edition; WAB = Western Aphasia Battery; WCST = Wisconsin Card Sorting Test; TMT = Trail Making Test; FAB = Frontal Assessment Battery; WMS-R = Wechsler Memory Scale—Revised; AVLT = Auditory Verbal Learning Test.

period during which he had been working for a company (the upper half of Table 2). The patient’s symptoms were consistent with focal/isolated retrograde amnesia, which means retrograde amnesia for a limited period without concomitant anterograde amnesia (Kopelman, 2000, 2002; Kapur, 2000).

He had been working continuously and extremely hard for about 6 months before the onset and had been worried about his impending marriage. There was no evidence of organic disease or trauma. On the basis of these findings and the criteria of the *Diagnostic and Statistical Manual of Mental Disorders, Fourth Edition* (American Psychiatric Association, 1994), we diagnosed his disorder as dissociative amnesia.

With the written informed consent of Patient 1, we performed a therapeutic session of interviews using intravenous injection of sodium thiopental to recover his memory (Kopelman, 2000). We made two attempts separated by a 10-day interval, after which all his memories from the first 4 years of his amnesic period were almost entirely recovered. However, most of the events that had occurred during the last half year of the amnesic period remained impaired (the upper half of Table 2).

Case Report on Patient 2

Patient 2 was a 52-year-old, right-handed, married man. He had normal developmental and educational histories and

Table 2. Amnesic Period of Patient 1 and Patient 2 and Changes with the Treatment

<i>Patient</i>	<i>Time Period</i>	<i>Before Treatment</i>	<i>After Treatment</i>	
Patient 1	Before the last half year of his college life	Retrieved	Retrieved	Nonamnesic
	The last half year of his college life and the first 3.5 years of his company life	Not retrieved	Retrieved	Amnesic and recovered
	The last half year of his company life	Not retrieved	Not retrieved	Amnesic and not recovered
Patient 2	Up to his time at high school	Retrieved	Retrieved	Nonamnesic
	From his time at university to onset	Not retrieved	Not retrieved	Amnesic and not recovered

had worked as a businessman for about 30 years after graduating from a university. He was described by his sister as an honest and gentle person.

One weekday morning, the car he was driving to work struck a guardrail. It is not known whether he lost consciousness temporarily, but he was clearly conscious when he was taken by ambulance to a nearby hospital. He was bruised, but radiographs did not reveal any further injuries, and computed tomography showed no abnormality in his brain, and he was prescribed analgesics. Although he had no physical problems, his company gave him a leave of absence from work to rest, and he stayed at home and experienced no problems with daily life. However, over a month later, when a colleague was talking to him on the telephone, they both became aware of his retrograde amnesia. He could recall nothing about the company, his job, and events over the last few decades. He said afterward that he had thought, “Who am I talking to? What is that company?” He was taken to see a doctor on that day, but no cause of his retrograde amnesia was detected, and it remained unchanged a few months later when he was admitted to our hospital.

Patient 2 was alert and cooperative. On the first day of our assessments, he said he could not recall any autobiographical memories after his graduation from high school except for the events and facts that he had learned from the people around him after onset, and his retrograde amnesia was later confirmed by the assessments. Although he said he was actually much burdened by his amnesic condition, he did not appear to appreciate its seriousness. His sister reported that he had been upset just after the onset but had gradually become more composed, and also that his personality remained unchanged. He had no physical or neurological symptoms. His blood, brain MRI, SPECT, and EEG were normal.

Patient 2 underwent almost the same assessments as Patient 1. Table 1 shows the results of neuropsychological examinations. His intelligence was quite good, and his attention, language, and frontal lobe function were normal. Examinations including the WMS-R showed that his anterograde memory was intact. For retrograde memory, he underwent the Autobiographical Memory Interview, the Crovitz Test, a personally adjusted Public Event and People Test, and a structured interview. These tests revealed that he had retrograde amnesia for almost all events after his

graduation from high school, that is, for a period of about 35 years (the lower half of Table 2). To summarize, his symptom was focal/isolated retrograde amnesia (Kopelman, 2000, 2002; Kapur, 2000) for a limited but extensive period.

He had been troubled for a few years about the negotiation for divorce with his wife, and he had got into debt, which had continued to increase gradually. There was no evidence of neurological disease or traumatic brain injury. On the basis of these findings and the criteria of the *Diagnostic and Statistical Manual of Mental Disorders, Fourth Edition* (American Psychiatric Association, 1994), we diagnosed the disorder of Patient 2 as dissociative retrograde amnesia.

With the written informed consent of Patient 2, we conducted interviews using sodium thiopental (Kopelman, 2000), but he was not able to recover any past memories (the lower half of Table 2). In fact, only one memory—the model of a car he had driven in his twenties—was retrieved during the interview, although this retrieved memory was again impaired after a sleep the patient had immediately after the interview.

Procedures

To clarify the brain mechanisms underlying memory repression, we performed an fMRI study with face and name recognition tasks. As was shown by the neuropsychological assessments mentioned above, both patients could easily retrieve autobiographical memories for the years between childhood and high school and could retrieve nothing about the company for which they recently worked. So we prepared, for each patient, three categories of face photographs and three categories of people’s names corresponding to the photographs: those of “recognizable” high school friends who were acquainted with and recognizable to the patients, those of “unrecognizable” colleagues from the company who were actually acquainted with but unrecognizable to the patients due to their memory impairments, and “control” distracters who were unacquainted with and unrecognizable to them. Each category consisted of 12 stimuli (12 face photographs or 12 people’s names). Each patient’s family members and colleagues cooperated in preparing those face photographs and people’s names, and the colleagues of each patient confirmed that

the unrecognizable faces and names were definitely acquainted with each of the patients. One difference in preparing the stimuli between the two patients was that only Patient 2 viewed each stimulus once a few days before fMRI scanning. We did this procedure for Patient 2 to exclude high school friends unacquainted with him due to normal forgetting because the period of retrograde amnesia of Patient 2 was very long, and it was possible that he had forgotten unimpressive high school friends naturally.

Two fMRI runs were carried out, the first with the face recognition task and the second with the name recognition task. We used a blocked design to maximize statistical power for single-subject analyses. In the face recognition task, the face photographs were presented one by one, and a block consisted of six faces. The presentation order of the face photographs was, for example, six recognizable faces, six unrecognizable faces, and six control faces followed by the “rest” block. Then patients were presented with the other six unrecognizable faces, the other six control faces, and the other six recognizable faces followed by the rest block. The order of presentation of the six faces in each block was randomized, and the order of the three categories was counterbalanced within the run. During fMRI, the participating patient was asked to indicate by pushing a button whether a person indicated by the presented face was personally acquainted with him. If he judged a person to be acquainted with, he was further asked to recall his relationship with the person or past events associated with that person. In the rest block, six mosaic images were presented, and the patient was asked only to look at them without pushing the button. To obtain reliable and reproducible results, each block was repeated three times throughout the run. Thus, the total number of presented faces was 108 (i.e., 36 recognizable faces, 36 unrecognizable faces, and 36 control faces), and the number of mosaic images was 36. Each stimulus was visually presented for 4000 msec with an interstimulus cross-fixation for 1000 msec. Therefore, one block continued for 30 sec, and the task continued for 12 min. Then the name recognition task was conducted, using the same procedure as for the face recognition task.

Both patients participated in the fMRI studies before and after treatment, that is, before and after Patient 1 recovered from retrograde amnesia (except for the last half year of the amnesic period) and before and after Patient 2 did not recover from retrograde amnesia. After treatment, we also asked Patient 1 to perform a “deception task.” The main task procedure was the same as for the original face and the name recognition tasks, except that Patient 1 was asked to simulate his amnesic condition before treatment, that is, by pretending not to remember his colleagues. We did not perform the deception task with Patient 2 because of his lack of recovery.

Data Acquisition and Statistical Analyses

Whole-brain imaging was performed with a 1.5-T General Electric Signa scanner. A T1-weighted image of each pa-

tient’s brain was obtained for coregistration in spatial preprocessing. A T2*-weighted EPI sequence sensitive to blood oxygenation level dependent contrast was used for functional imaging under the following parameters: time to repeat = 2500 msec, time to echo = 30 msec, flip angle = 90°, 64 × 64 acquisition matrix, field of view = 260 mm, 26 axial slices with a slice thickness of 4 mm, and an interslice gap of 1 mm.

Data were analyzed using SPM5 (Wellcome Department of Imaging Neuroscience, London, UK). All EPI images were realigned to correct for small movements between scans. A T1-weighted structural MRI was coregistered to the mean image of realigned EPI images. Then the coregistered T1 image was normalized to the T1 template based on the Montreal Neurological Institute (MNI) reference brain. Using the parameters from this normalization process, the EPI images were reformatted to isometric voxels (resampled voxel size = 2 mm) and smoothed with a 10-mm FWHM Gaussian kernel.

The fMRI data were analyzed using the blocked design, and we combined the data over the two kinds of tasks (i.e., the face and the name recognition tasks) to increase statistical power. Activated voxels in each experimental condition of interest (i.e., recognizable, unrecognizable, and control conditions) were identified using a statistical model containing boxcar function convolved with a canonical hemodynamic response function. For assessment, the following contrasts were created: (a) unrecognizable colleagues versus recognizable high school friends; (b) recognizable high school friends versus unrecognizable colleagues; (c) unrecognizable colleagues versus control unfamiliar people; and (d) control unfamiliar people versus unrecognizable colleagues. Our main analysis was the comparison between the recognizable and the unrecognizable conditions (i.e., contrasts a and b), in both of which the patients were presented with the faces/names of people who were acquainted with them before the onset. In these main analyses, the threshold of significance was set at $p < .001$ (uncorrected for multiple comparisons), with the extent threshold of 50 contiguous voxels. Among significantly activated regions in these analyses, the regions that survived correction at $p < .05$ (with the extent threshold of 50 contiguous voxels) were also reported. Comparisons involving the control condition (i.e., contrasts c and d) were used for inclusive masking for the main analyses, and the threshold was set at $p < .05$ (uncorrected for multiple comparisons).

RESULTS

Patient 1

Before treatment, Patient 1 judged all of the recognizable stimuli to be acquainted with him and all of the unrecognizable and the control stimuli to be unacquainted with him during the fMRI experiment. After treatment, he judged all of the recognizable stimuli to be acquainted with him and all of the control stimuli to be unacquainted with him. Also

after treatment, he judged one of the unrecognizable face stimuli to be unacquainted with him but the other unrecognizable face stimuli and all of the unrecognizable name stimuli to be acquainted with him due to the recovery of his memory.

With regard to brain activations, to investigate whether the pFC was activated during the unrecognizable condition, we first compared the unrecognizable condition with the recognizable condition ($p < .001$, uncorrected, $k > 50$), with inclusive masking of the unrecognizable condition with the control condition. This masking was added to identify regions showing enhanced activity during the unrecognizable condition relative not only to the recognizable condition but also to the baseline control condition. The results obtained before treatment revealed significant activations in the pFC, including the right DLPFC [Brodmann's area (BA) 9/10/46], the left DLPFC (BA 46), the right ventrolateral pFC (VLPFC; BA 47), and the left VLPFC (BA 47; Figure 1A; Table 3).

Second, to investigate whether the MTL was deactivated during the unrecognizable condition, we compared the recognizable condition with the unrecognizable condition ($p < .001$, uncorrected, $k > 50$), with inclusive masking of the control condition with the unrecognizable condition. This masking was added to identify the regions that showed decreased activity during the unrecognizable condition relative not only to the recognizable condition but also to the control condition. The results obtained before treatment revealed a significant difference in the left hippocampus (Table 3), indicating that the left hippocampus was more deactivated during the unrecognizable condition than during either the recog-

nizable or the control condition. To rule out the possibility that this difference was derived from the successful retrieval of high school friends in the recognizable condition, we further compared the recognizable condition with the control condition ($p < .001$, uncorrected, $k > 50$). The results revealed no significant activity in the MTL, indicating that the significant difference in the hippocampus during the recognizable condition relative to the unrecognizable condition was not due to "activation" in the former but rather to decreased activity in the latter (Figure 1B). In the fMRI study after treatment, neither of the DLPFC activations nor of the left hippocampus deactivation was found in each contrast (Table 3). The results indicate that this altered pattern of brain activation was characteristic of the amnesic state.

In addition, we asked Patient 1 to perform a deception task after treatment, in which the task procedure was the same as that of the original face and name recognition tasks, except that he was requested to simulate the amnesic condition before treatment; that is, he was asked to pretend not to remember the unrecognizable colleagues. Patient 1 perfectly simulated the before-treatment amnesic condition. We compared the unrecognizable condition with the recognizable condition ($p < .001$, uncorrected, $k > 50$) and found significant activations in the left DLPFC, the right VLPFC, and the left VLPFC (Figure 2; Table 4). These regions partially overlapped with those detected during the unrecognizable condition compared with the recognizable condition in the results obtained before treatment. However, the right DLPFC activation found before treatment was not observed in the deception task. In the MTL, decreased activity was not

Figure 1. Brain activations of Patient 1 before treatment. (A) The unrecognizable condition relative to the recognizable condition (with inclusive masking of the unrecognizable condition vs. the control condition). Significant activations were found in the DLPFC and the VLPFC bilaterally. (B) The recognizable condition relative to the unrecognizable condition (with inclusive masking of the control condition vs. the unrecognizable condition). A significant difference was found in the left hippocampus, indicating that the left hippocampus was more deactivated during the unrecognizable condition than during the two other conditions. After the patient's memory recovery after treatment, these altered patterns of brain activation disappeared.

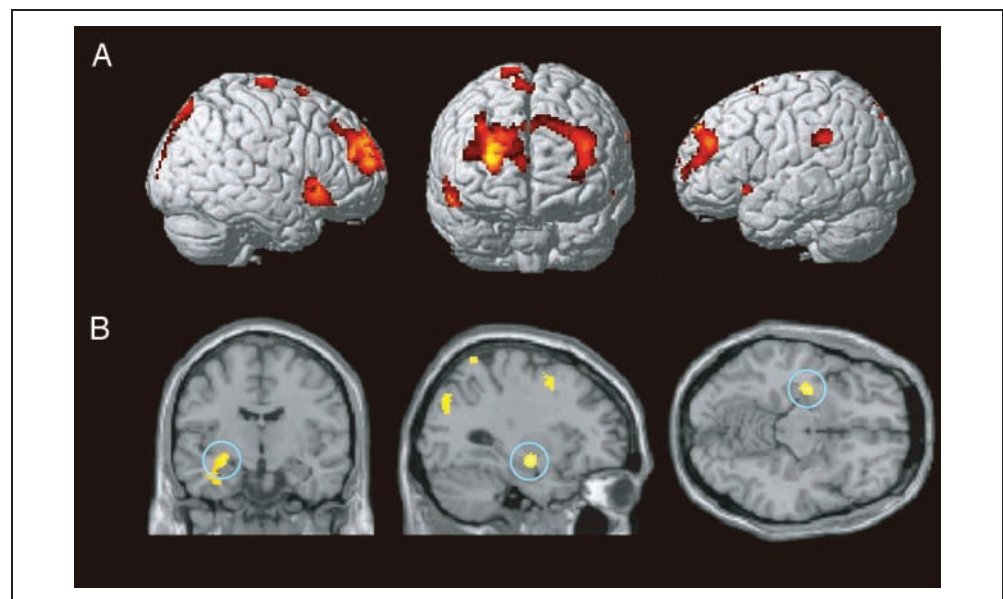


Table 3. Brain Regions Showing Activations of Patient 1 before and after the Treatment

Region (BA)	Coordinates				Cluster Size
	x	y	z	Z	
<i>Unrecognizable relative to recognizable (with the masking of unrecognizable relative to control) before the treatment</i>					
Rt superior/middle frontal gyrus (9/10/46) [extending to Lt middle frontal gyrus (9/46)]*	28	60	16	6.40	2157
Rt inferior frontal gyrus (47)*	50	24	-10	5.52	445
Rt SMA (6)	8	8	66	4.15	118
Rt SMA (6/4)	10	-18	74	4.29	178
Rt/Lt lingual gyrus/cuneus (17/18)	0	-90	0	4.88	1147
Lt inferior frontal gyrus (47)	-50	20	-8	3.82	58
Lt supramarginal gyrus (40)	-66	-40	34	4.30	149
<i>Recognizable relative to unrecognizable (with the masking of control relative to unrecognizable) before the treatment</i>					
Rt inferior frontal gyrus (44)	28	8	34	3.57	57
Rt cerebellum	34	-36	-34	3.86	91
Rt cerebellum	38	-64	-50	4.76	194
Rt cerebellum	8	-64	-24	3.60	82
Lt precentral gyrus (6)	-32	4	50	3.66	88
Lt hippocampus	-30	-10	-12	3.93	216
Lt postcentral gyrus (3)	-46	-16	30	3.47	56
Lt thalamus	-20	-26	12	4.26	160
Lt superior parietal lobule (5)	-20	-52	72	4.29	119
Lt middle occipital gyrus (19/39)	-36	-76	32	4.48	396
<i>Unrecognizable relative to recognizable (with the masking of unrecognizable relative to control) after the treatment</i>					
No suprathreshold activations					
<i>Recognizable relative to unrecognizable (with the masking of control relative to unrecognizable) after the treatment</i>					
Rt supramarginal gyrus (40)	64	-32	40	3.85	120

Rt = right; Lt = left.

*The region that survived a more stringent threshold of $p < .05$ (corrected for multiple comparisons).

Figure 2. Brain activations of Patient 1 in the deception task. The figure shows activations during the unrecognizable condition relative to the recognizable condition. Significant activations were found in the left DLPFC and bilateral VLPFC. Although these activations partially overlapped with those found before treatment, the activation in the right DLPFC found before treatment was not detected in this deception task.

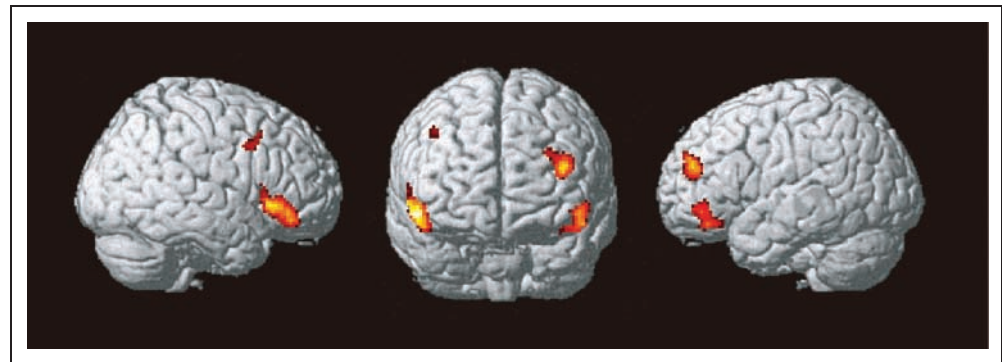


Table 4. Brain Regions Showing Activations of Patient 1 in the Deception Task

Region (BA)	Coordinates			Z	Cluster Size
	x	y	z		
<i>Unrecognizable relative to recognizable</i>					
Rt inferior frontal gyrus (47)	54	28	-6	4.49	451
Rt inferior frontal sulcus (44)	42	14	38	3.42	68
Lt middle frontal gyrus (46)	-38	48	20	4.40	224
Lt inferior frontal gyrus (47/45)	-50	40	-8	4.01	221
<i>Recognizable relative to unrecognizable</i>					
No suprathreshold activations					

Rt = right; Lt = left.

found in the unrecognizable condition compared with the recognizable condition ($p < .001$, uncorrected, $k > 50$).

Patient 2

Patient 2 judged all of the recognizable stimuli to be acquainted with him and all of the unrecognizable and the control stimuli to be unacquainted with him during the fMRI measurements performed both before and after treatment. (Patient 2 did not recover from retrograde amnesia.)

In the analysis of the fMRI data of Patient 2 obtained before treatment, we first compared the unrecognizable condition with the recognizable condition ($p < .001$, uncorrected, $k > 50$), with inclusive masking of the unrecog-

nizable condition with the control condition. Significant activations were found in the bilateral DLPFC (Figure 3A; Table 5). Activation in the right DLPFC was found in almost the same region as in Patient 1.

As for the MTL, we compared the recognizable condition with the unrecognizable condition ($p < .001$, uncorrected, $k > 50$), with inclusive masking of the control condition with the unrecognizable condition, and found that the right hippocampus was deactivated during the unrecognizable condition (Figure 3B). After treatment, the activation status remained basically unchanged: Activations in the bilateral DLPFC and deactivation in the right hippocampus were again found during the unrecognizable condition (Figure 4; Table 5). We did not perform the deception task for Patient 2 because he had not recovered.

DISCUSSION

The present fMRI study revealed that increased activity in the pFC and decreased activity in the hippocampus are associated with dissociative amnesia. After treatment for retrograde amnesia, these activation changes disappeared in one patient, as his retrograde memories were recovered, whereas they remained unchanged in the other patient, as his retrograde memories were not recovered. These results strongly indicate that the changes in activation were specific to the patients' deficit in the retrieval of retrograde memories.

In the present study, we could assess two patients with dissociative amnesia systematically by comparing brain activations between viewing unrecognizable stimuli from amnesic period and viewing recognizable stimuli from nonamnesic period because both patients had profound

Figure 3. Brain activations of Patient 2 before treatment. (A) The unrecognizable condition relative to the recognizable condition (with inclusive masking of the unrecognizable condition vs. the control condition). Significant activations were found in the bilateral DLPFC. (B) The recognizable condition relative to the unrecognizable condition (with inclusive masking of the control condition vs. the unrecognizable condition). A significant difference was found in the right hippocampus, indicating that the right hippocampus was more deactivated during the unrecognizable condition than during the two other conditions.

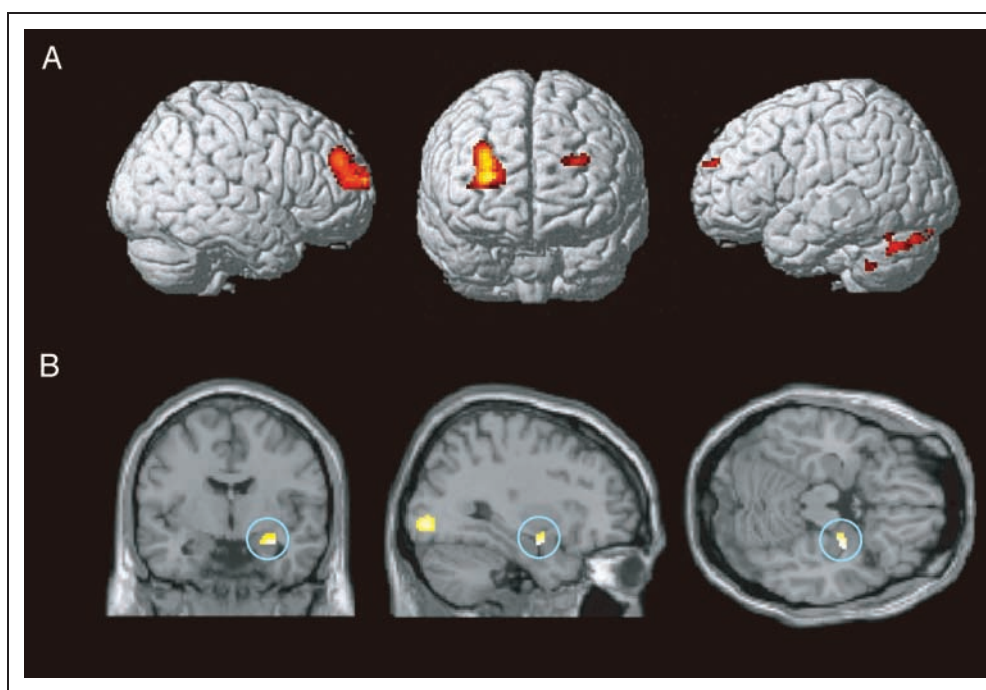
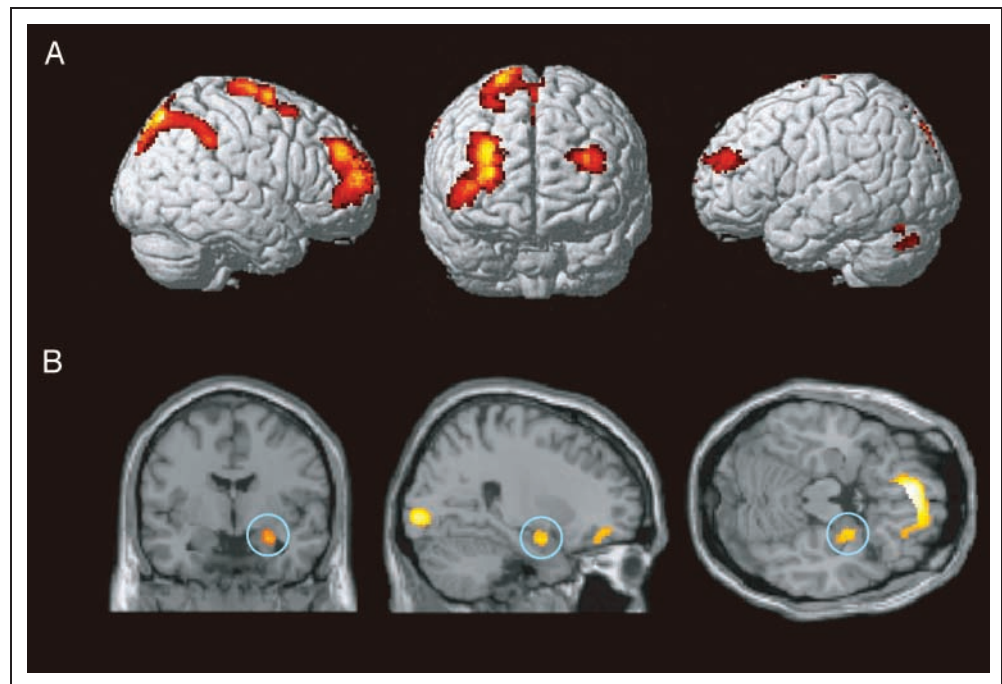


Figure 4. Brain activations of Patient 2 after treatment. (A) The unrecognizable condition relative to the recognizable condition (with inclusive masking of the unrecognizable condition vs. the control condition). Significant activations were found in the bilateral DLPFC, as found before treatment. (B) The recognizable condition relative to the unrecognizable condition (with inclusive masking of the control condition vs. the unrecognizable condition). A significant difference was found in the right hippocampus, as was found before treatment.



and time-limited retrograde amnesia. Moreover, after treatment, they showed different courses of amnesia, which were accompanied by strikingly contrasted courses of the altered brain activation. We believe these factors made the present study a strong one compared with previous neuroimaging studies (Hennig-Fast et al., 2008; Botzung et al., 2007; Yang et al., 2005; Yasuno et al., 2000; Markowitsch, Calabrese, et al., 1997; Markowitsch, Fink, et al., 1997). The findings obtained from these previous studies are diverse, although recent fMRI studies have reported hippocampal deactivation (Hennig-Fast et al., 2008; Botzung et al., 2007; Yang et al., 2005). We do not know the precise reason for this diversity, but one possible reason is that these studies vary from one another in patients' symptoms (e.g., amnesia with and without loss of personal identity) and experimental paradigms.

Consistent with the results of previous studies showing activation loss in the MTL (Hennig-Fast et al., 2008; Botzung et al., 2007; Yang et al., 2005), deactivation was found in the hippocampus during the unrecognizable condition compared with during the recognizable and the control conditions in both of the patients. Because activation in the hippocampus is likely to index the retrieval success accompanied by conscious recollection of past episodes (e.g., Eldridge, Knowlton, Furmanski, Bookheimer, & Engel, 2000), the deactivated hippocampus indicates that the retrieval of memories is inhibited, hence the patients were unable to retrieve their retrograde memories. In other words, deactivation of the hippocampus may be a reflection of the retrieval deficit itself, and it might be the result of a repressing effect exerted on the hippocampus from other brain regions.

One critical contender for the role of repressor is probably, among the prefrontal regions, the DLPFC because this region was consistently active in both patients during the unrecognizable conditions relative to the recognizable and the control conditions. This interpretation is consistent with the current theoretical model of dissociative amnesia (Kopelman, 2000, 2002), in which stress predominantly affects the frontal control/executive systems, such that the retrieval of autobiographical memories is inhibited. Our results are also consistent with those of fMRI studies of the voluntary forgetting process of healthy subjects (Depue et al., 2007; Anderson et al., 2004) and of posthypnotic amnesia with subjects susceptible to hypnosis (Mendelsohn et al., 2008), in that prefrontal activation has been consistently detected in the context of memory suppression. On the basis of systematic investigation, our findings are the first to indicate that such memory repression associated with the DLPFC activation also occurs during memory retrieval in patients with dissociative amnesia.

However, there might be another possible interpretation for the prefrontal activation and hippocampal deactivation, in which some unknown mechanism causes hippocampal deactivation and inhibition of memory retrieval, and then follows prefrontal activation that indicates a particularly strong effort to retrieve the memories. In fact, we have no evidence that prefrontal activation induces hippocampal deactivation in the present fMRI study. If time resolution in the analysis of fMRI data is improved and event-related fMRI with the task of judging each item's status of the acquaintance is used, the order and roles of activation of several regions might be elucidated, although such findings themselves cannot prove the causality of the

Table 5. Brain Regions Showing Activations of Patient 2 before and after the Treatment

Region (BA)	Coordinates			Z	Cluster Size
	x	y	z		
<i>Unrecognizable relative to recognizable (with the masking of unrecognizable relative to control) before the treatment</i>					
Rt middle frontal gyrus (46)	30	48	30	5.18	773
Lt superior frontal gyrus (9)	-30	60	28	3.88	80
Lt cerebellum	-34	-48	-44	3.99	50
Lt lingual gyrus (17/18)	-4	-68	4	4.46	135
Lt cerebellum	-36	-68	-30	4.00	195
Lt cerebellum	-8	-90	-22	4.04	94
Lt cuneus/calcarine sulcus (18/17)	-4	-94	12	3.54	51
<i>Recognizable relative to unrecognizable (with the masking of control relative to unrecognizable) before the treatment</i>					
Rt hippocampus	32	-6	-18	4.46	66
Rt inferior/middle occipital gyrus (19/18)	32	-84	-2	4.06	199
Lt middle occipital/temporal gyrus (39)	-42	-72	20	4.09	98
Lt lingual/inferior occipital gyrus (18/19)	-28	-88	-10	4.54	273
<i>Unrecognizable relative to recognizable (with the masking of unrecognizable relative to control) after the treatment</i>					
Rt middle frontal gyrus (46)*	30	50	30	7.59	1707
Rt SMA (6)*	6	2	54	6.84	1380
Rt cuneus (19) [extending to Rt supramarginal gyrus (40)]*	12	-80	44	7.15	3040
Lt middle frontal gyrus (46)	-36	54	26	5.05	477
Lt cerebellum	-26	-68	-26	5.14	273
<i>Recognizable relative to unrecognizable (with the masking of control relative to unrecognizable) after the treatment</i>					
Rt OFC (11/25)	14	16	-14	3.61	57
Rt hippocampus	26	-4	-18	4.14	107
Rt inferior temporal gyrus (20)	40	-10	-42	4.78	128
Rt precentral gyrus (4)	54	-14	58	4.92	271
Rt middle/inferior occipital gyrus (18)*	28	-92	-2	6.20	397
Rt/Lt OFC (11)*	0	46	-22	6.56	1636
Lt inferior occipital gyrus (18)*	-18	-96	-8	6.08	533

Rt = right; Lt = left.

*The region that survived a more stringent threshold of $p < .05$ (corrected for multiple comparisons).

activation/deactivation of different regions. Transcranial magnetic stimulation might be useful to find the causality between the activation/deactivation of plural brain regions. For instance, if the inhibitory stimulation to the right pFC of patients with dissociative amnesia gives rise to the improvement of memory retrieval and the disappearance of hippocampal deactivation, one can argue that prefrontal activation induces hippocampal deactivation in patients with dissociative amnesia.

The results of the deception task, performed by Patient 1 after his memory was recovered after treatment, indicate two further important points. First, consistent with the idea that the prefrontal executive system supports deceptive behavior (Sip, Roepstorff, McGregor, & Frith, 2008; Spence et al., 2004) and with the results of some previous neuroimaging studies (e.g., Abe et al., 2006; Spence et al., 2001), simulating amnesia was associated with increased activity of the left DLPFC and bilateral

VLPFC, both of which were also activated before treatment. However, the right DLPFC, a region consistently active during the amnesic state with a large cluster size in both patients, was not activated. This finding suggests that the right relative to the left DLPFC has a predominant, specific, and pivotal role in memory repression. Second, fMRI may provide useful information for discriminating malingering from real diseases. Some previous studies have also reported supportive evidence for this practical use of functional imaging (Glisky et al., 2004; Spence, Crimlisk, Cope, Ron, & Grasby, 2000; Costello, Fletcher, & Dolan, 1998).

In conclusion, our findings provide direct evidence that memory repression in dissociative amnesia is associated with an altered pattern of neural activity, and they also provide an important clue for understanding the memory control system in the context of Freud's theory of involuntary memory repression. Our findings cannot prove causal relationships between increased activity in the pFC and decreased activity in the hippocampus. We can only speculate that excessive activation in the DLPFC, especially the right DLPFC, might have an inhibitory effect on hippocampal activity, and hippocampal deactivation is likely to cause a deficit in the retrieval of retrograde memories in dissociative amnesia. To prove this true, studies with many patients using more sophisticated methods are needed in the future.

Acknowledgments

We thank Dr. Suguru Sato (Department of Neurology, Sendai Medical Center, National Hospital Organization) and Dr. Takashi Kikuchi (Department of Psychiatry, Sendai Medical Center, National Hospital Organization) for referring their patient to us.

Reprint requests should be sent to Hirokazu Kikuchi, Department of Behavioral Neurology and Cognitive Neuroscience, Tohoku University Graduate School of Medicine, 2-1 Seiryomachi, Aoba-ku, Sendai 980-8575, Japan, or via e-mail: kiku0215@mail.tains.tohoku.ac.jp.

REFERENCES

Abe, N., Suzuki, M., Tsukiura, T., Mori, E., Yamaguchi, K., Itoh, M., et al. (2006). Dissociable roles of prefrontal and anterior cingulate cortices in deception. *Cerebral Cortex*, *16*, 192–199.

American Psychiatric Association. (1994). *Diagnostic and statistical manual of mental disorders* (4th ed., pp. 478–481). Washington, DC: American Psychiatric Press.

Anderson, M. C., & Green, C. (2001). Suppressing unwanted memories by executive control. *Nature*, *410*, 366–369.

Anderson, M. C., & Levy, B. (2002). Repression can (and should) be studied empirically. *Trends in Cognitive Sciences*, *6*, 502–503.

Anderson, M. C., Ochsner, K. N., Kuhl, B., Cooper, J., Robertson, E., Gabrieli, S. W., et al. (2004). Neural systems underlying the suppression of unwanted memories. *Science*, *303*, 232–235.

Botzung, A., Denkova, E., & Manning, L. (2007). Psychogenic

memory deficits associated with functional cerebral changes: An fMRI study. *Neurocase*, *13*, 378–384.

Costello, A., Fletcher, P. C., & Dolan, R. J. (1998). The origins of forgetting in a case of isolated retrograde amnesia following a haemorrhage: Evidence from functional imaging. *Neurocase*, *4*, 437–446.

de Kloet, E. R., Oitzl, M. S., & Joels, M. (1999). Stress and cognition: Are corticosteroids good or bad guys? *Trends in Neurosciences*, *22*, 422–426.

Depue, B. E., Banich, M. T., & Curran, T. (2006). Suppression of emotional and nonemotional content in memory: Effects of repetition on cognitive control. *Psychological Science*, *17*, 441–447.

Depue, B. E., Curran, T., & Banich, M. T. (2007). Prefrontal regions orchestrate suppression of emotional memories via a two-phase process. *Science*, *317*, 215–219.

Eldridge, L. L., Knowlton, B. J., Furmanski, C. S., Bookheimer, S. Y., & Engel, S. A. (2000). Remembering episodes: A selective role for the hippocampus during retrieval. *Nature Neuroscience*, *3*, 1149–1152.

Erdelyi, M. H. (2006). The unified theory of repression. *Behavioral and Brain Sciences*, *29*, 499–511.

Freud, S. (1966). In J. Strachey (Ed.), *The standard edition of the complete psychological works of Sigmund Freud* (Vol. 1, pp. 117–128). London: Hogarth.

Glisky, E. L., Ryan, L., Reminger, S., Hardt, O., Hayes, S. M., & Hupbach, A. (2004). A case of psychogenic fugue: I understand, aber ich verstehe nichts. *Neuropsychologia*, *42*, 1132–1147.

Hennig-Fast, K., Meister, F., Frodl, T., Beraldi, A., Padberg, F., Engel, R. R., et al. (2008). A case of persistent retrograde amnesia following a dissociative fugue: Neuropsychological and neurofunctional underpinnings of loss of autobiographical memory and self-awareness. *Neuropsychologia*, *46*, 2993–3005.

Kaplan, H. I., & Sadock, B. J. (1995). *Comprehensive textbook of psychiatry* (6th ed., pp. 650–653). New York: William & Wilkins.

Kapur, N. (2000). Focal retrograde amnesia and the attribution of causality: An exceptionally benign commentary. *Cognitive Neuropsychology*, *17*, 623–637.

Kihlstrom, J. F. (2002). No need for repression. *Trends in Cognitive Sciences*, *6*, 502.

Kopelman, M. D. (2000). Focal retrograde amnesia and the attribution of causality: An exceptionally critical review. *Cognitive Neuropsychology*, *17*, 585–621.

Kopelman, M. D. (2002). Disorders of memory. *Brain*, *125*, 2152–2190.

Markowitsch, H. J. (1999). Functional neuroimaging correlates of functional amnesia. *Memory*, *7*, 561–583.

Markowitsch, H. J. (2003). Psychogenic amnesia. *Neuroimage*, *20*(Suppl. 1), S132–S138.

Markowitsch, H. J., Calabrese, P., Fink, G. R., Durwen, H. F., Kessler, J., Harting, C., et al. (1997). Impaired episodic memory retrieval in a case of probable psychogenic amnesia. *Psychiatry Research*, *74*, 119–126.

Markowitsch, H. J., Fink, G. R., Thone, A., Kessler, J., & Heiss, W. D. (1997). A PET study of persistent psychogenic amnesia covering the whole life span. *Cognitive Neuropsychiatry*, *2*, 135–158.

Mendelsohn, A., Chalamish, Y., Solomonovich, A., & Dudai, Y. (2008). Mesmerizing memories: Brain substrates of episodic memory suppression in posthypnotic amnesia. *Neuron*, *57*, 159–170.

Schacter, D. L. (2001). Suppression of unwanted memories: Repression revisited? *Lancet*, *357*, 1724–1725.

Sip, K. E., Roepstorff, A., McGregor, W., & Frith, C. D. (2008). Detecting deception: The scope and limits. *Trends in Cognitive Sciences*, *12*, 48–53.

- Spence, S. A., Crimlisk, H. L., Cope, H., Ron, M. A., & Grasby, P. M. (2000). Discrete neurophysiological correlates in prefrontal cortex during hysterical and feigned disorder of movement. *Lancet*, *355*, 1243–1244.
- Spence, S. A., Farrow, T. F., Herford, A. E., Wilkinson, I. D., Zheng, Y., & Woodruff, P. W. (2001). Behavioural and functional anatomical correlates of deception in humans. *NeuroReport*, *12*, 2849–2853.
- Spence, S. A., Hunter, M. D., Farrow, T. F., Green, R. D., Leung, D. H., Hughes, C. J., et al. (2004). A cognitive neurobiological account of deception: Evidence from functional neuroimaging. *Philosophical Transactions of the Royal Society of London, Series B, Biological Sciences*, *359*, 1755–1762.
- Yang, J. C., Jeong, G. W., Lee, M. S., Kang, H. K., Eun, S. J., Kim, Y. K., et al. (2005). Functional MR imaging of psychogenic amnesia: A case report. *Korean Journal of Radiology*, *6*, 196–199.
- Yasuno, F., Nishikawa, T., Nakagawa, Y., Ikejiri, Y., Tokunaga, H., Mizuta, I., et al. (2000). Functional anatomical study of psychogenic amnesia. *Psychiatry Research*, *99*, 43–57.